



Elsevier has created a [Monkeypox Information Center](#) in response to the declared public health emergency of international concern, with free information in English on the monkeypox virus. The Monkeypox Information Center is hosted on Elsevier Connect, the company's public news and information website.

Elsevier hereby grants permission to make all its monkeypox related research that is available on the Monkeypox Information Center - including this research content - immediately available in publicly funded repositories, with rights for unrestricted research re-use and analyses in any form or by any means with acknowledgement of the original source. These permissions are granted for free by Elsevier for as long as the Monkeypox Information Center remains active.

Oral lesions in human monkeypox disease and their management—a scoping review

Betsy Joseph, MDS, PhD, MFDS,^a and Sukumaran Anil, BDS, MDS, PhD, FRCPath, FDSRCS^{b,c}

Objective. Monkeypox (MPX) disease poses a threat to the frontline health workers, including dental practitioners; however, there is limited literature on its dental implications. The objective of this scoping review was to map the oral manifestations of MPX and its management based on existing information.

Materials and Methods. Articles published up to July 31, 2022 were searched to select relevant observational and experimental studies in humans who reported oral lesions in MPX disease, including case reports. The findings of this review are based on the pooled data of 1,136 patients (age range: 2-52 years) reported from different parts of the world.

Results. Oral lesions included mouth sores, oral mucosal lesions, ulcers on the tongue, tongue swelling, pustular lesions on the gingiva, perioral erosive lesions, oral candidiasis, and oropharyngeal lesions. Oral lesions of MPX infection and their management strategies are relevant to dentists. Dental practitioners may be the first to detect the initial symptoms of MPX disease.

Conclusion. Oral lesions may present as initial lesions of MPX suggesting that dentists and dental personnel should be aware of the nature of the disease. Clinicians must be alert to rashes resembling MPX lesions and distinguish MPX from herpetic and similar vesicular-bullous lesions for differential diagnosis. Symptomatic and supportive care for oral lesions is important. (Oral Surg Oral Med Oral Pathol Oral Radiol 2022;000:1–8)

The emergence of monkeypox (MPX) in humans is a global concern during the current COVID-19 crisis. Human MPX is a viral disease of animal origin (zoonosis) caused by a virus of the orthopox family and is closely associated with smallpox viruses. Although the first case was reported in the mid-1900s in Africa, it is now spreading to different parts of the world, which has led the World Health Organization (WHO) to declare it as a “global emergency.” Monkeypox virus (MPXV) infections have been reported in African countries, high-income settings (i.e., USA, Canada, Australia, Singapore) and several European countries (i.e., UK, Sweden, Spain, Portugal, Netherlands, Italy, Germany, Belgium, and France).¹

New cases have been reported in Europe without any travel history to Africa or history of contact with infected persons.² One of the hypotheses regarding the current outbreak is the general decline in the population’s immunity to smallpox and similar orthopox

virus diseases, as the smallpox vaccination program was discontinued 30 years ago.³ The cases of MPXV infections mostly occurred among young adults and small children who were unvaccinated against smallpox⁴ and had no other comorbidity.^{5–7} In some cases, patients <18 years were more likely to be hospitalized.⁸ The incubation period from initial animal exposure to the onset of illness ranged from 11 to 18 days.^{5,8}

The clinical features include fever, rash, sweats, chills, lymphadenopathy, headache, stiff neck, red eyes, runny nose, sore throat, cough, wheezing, nausea and/or vomiting, abdominal pain, scrotal lump, itchy maculopapular rashes, and confusion.^{5,8} Concurrent rashes range from 5 to 25 (benign) to 101 to 250 (grave) lesions, depending on the cases.^{5,7} Oral lesions are found in many cases^{7,9}; however, there are also reports of cases without oral manifestations.¹⁰ When present, these lesions can be infectious until all the lesions are crusted.¹¹ Although there is no conclusive evidence of how the infection spreads, a primary animal-to-human infection by direct or indirect contact with the body fluid of an MPXV-infected animal¹² is evident. Broken skin, mucosa of the eyes, nose, mouth,

^aDepartment of Periodontics, Saveetha Dental College and Hospital, Saveetha Institute of Medical and Technical Sciences, Chennai, Tamil Nadu, India.

^bDepartment of Dentistry, Oral Health Institute, Hamad Medical Corporation, Doha, Qatar.

^cCollege of Dental Medicine, Qatar University, Doha, Qatar.

Corresponding author: Anil Sukumaran, E-mail address: drsamil@gmail.com

Received for publication Sep 15, 2022; returned for revision Nov 10, 2022; accepted for publication Nov 27, 2022.

© 2022 The Author(s). Published by Elsevier Inc. This is an open access article under the CC BY license (<http://creativecommons.org/licenses/by/4.0/>)

2212-4403/\$-see front matter

<https://doi.org/10.1016/j.oooo.2022.11.012>

Statement of Clinical Relevance

The oral lesions of monkeypox infection and their management are pertinent for clinicians. Dental practitioners may be the first to identify monkeypox lesions and should be more cautious while examining patients with fever and lymphadenopathy

and respiratory tract are possible routes of viral entry to the body.¹²

Human transmission is often documented through contact with respiratory droplets, body fluids, lesion material, and contaminated clothes.¹³ This transmission mode has been considered a significant threat to community health after the 2018 Nigerian outbreak. Diagnosis is made based on viremia, samples from upper respiratory tract swabs, and the presence of MPXV DNA by multiple molecular assays, especially polymerase chain reaction of the samples collected from the lesions.¹³

In July 2022, the WHO declared MPX infection a public health emergency of international concern. This should alert the frontline health workers, including dental practitioners, to the high risk of developing MPX disease if they come in contact with infected patients and their body fluids. We have witnessed the catastrophic impact of the COVID-19 pandemic on dentists and dental practices. In this context, it is necessary to discuss the implications of MPXV infections on dental practice. Therefore, the objective of this scoping review was to map the oral manifestations of MPX disease and its management based on existing information.

MATERIALS AND METHODS

This scoping review aimed to map the oral manifestations of MPX disease and its management, based on existing information. The Preferred Reporting Items for Systematic Reviews and Meta-Analyses extension for Scoping Reviews checklist was used. The protocol was prepared after a preliminary search of existing literature.

Eligibility criteria

Articles published up to August 15, 2022 were searched to select appropriate studies using the following Population/Concept/Context framework: *Population*: Human patients (all ages); *Concept*: Case reports, observational, and experimental studies; *Context*: MPX disease in humans. Case reports and observational and experimental studies conducted in English were included in this review. However, in vitro and in vivo studies, editorials, commentaries, letters to the editor, conference papers, and consensus papers were excluded.

Search strategy

Prominent literature databases, such as MEDLINE/PubMed, Scopus, Google Scholar, and Web of Science, were extensively searched on August 15, 2022. The search was conducted based on “Monkeypox” and “Oral lesions,” which are the key concepts in the research question. Literature that contained the MeSH terms, keywords, and other free terms related to “monkeypox,” “monkeypox,” “monkeypox virus,”

“monkeypox virus,” “MPX,” “MPXV,” “oral lesions,” “oral ulcers,” “mouth,” “perioral,” “pharynx,” “oropharynx,” and “nasopharynx” were searched with Boolean operators and included in the initial screening. In addition, preprints (medrxiv and biorxiv) were searched. The full text of the selected articles was read in detail, and the evidence was corroborated in this review.

A preliminary search identified 45 eligible studies, of which 12 were excluded during the screening of title and abstract based on the eligibility criteria. Duplicates were removed using the reference manager (Endnote), and 2 reviewers examined the remaining 33 articles in full length based on the eligibility criteria. In cases of disagreement, a third reviewer resolved the differences through a discussion. Finally, 21 studies were excluded where oral manifestations were not described, and the remaining 12 studies were included where oral lesions in human MPX disease were reported (Figure 1).

The relevant data were selected and recorded by 2 reviewers. The author’s name, year of publication, country, mean age, sample size, study design, oral lesions, management of oral lesions, remarks assessed, results, and conclusions were charted for all the included studies.

RESULTS

The findings of this review were based on the pooled data of 1136 patients (age range: 2–52 years) reported in case reports, retrospective observational studies, and prospective cohort studies from different parts of the world (i.e., USA, UK, Nigeria, Spain, and Korea; Table I). Only 1 study included epidemiologic reports from multiple (16) countries.⁷

Oral lesions included mouth sores,^{8,17,22} oral mucosal lesions,^{7,8,13,15,16,19,21} ulcers on the tongue,^{7,21} tongue swelling,²¹ epiglottitis,⁷ pustular lesions on the gingiva,¹⁸ perioral erosive lesions,^{20,21} oral candidiasis,²¹ and pharyngeal,²² oropharyngeal,^{7,17,18} and tonsillar lesions^{7,18} (Table II). Generalized lymphadenopathy was a common feature,^{7,8,13,14,16} whereas sore throat was also reported in a few cases.^{15,16,20,21}

The specific management of these lesions has not been mentioned in most reports. Tonsillar edema andodynophagia improved slowly after initiation of tecovirimat for systemic lesions, and the patient recovered after 5 days.¹⁸ The Magic mouthwash, intravenous fluconazole for oral candidiasis, and an intramuscular dose of penicillin were administered along with supportive care.²¹

DISCUSSION

Oral lesions

Various presentations of oral lesions have been reported in several cases of human MPX infections

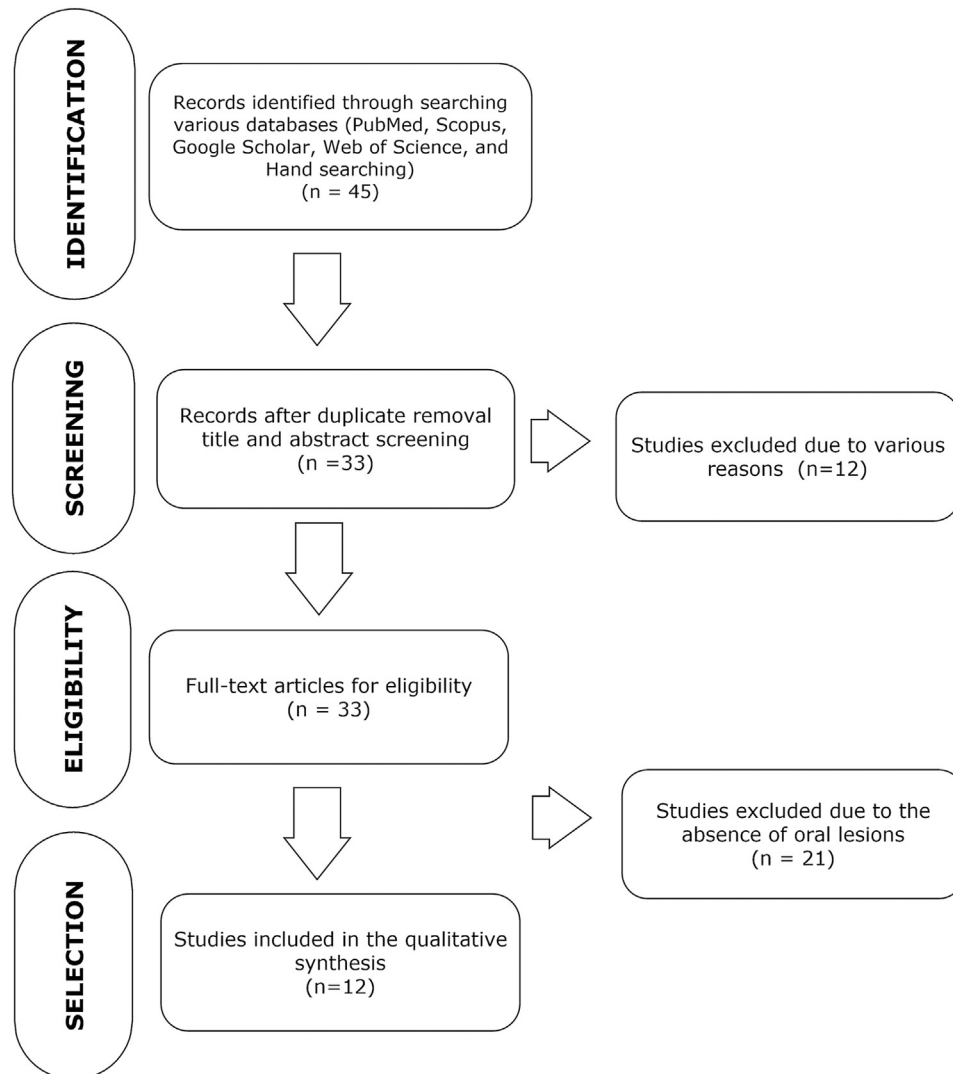


Fig. 1. Preferred Reporting Items for Systematic Reviews and Meta-Analyses flowchart.

(Figures 2A and 2B). The oral mucosa may present with lesions that transform from vesicles to pustules, including umbilication and crusting, within 1 to 4 weeks.^{7,14,21,23} These lesions may appear in the oral cavity and then follow the skin around the extremities in a centrifugal pattern, along with fever and lymphadenopathy.^{24–26} Few patients may have oropharyngeal symptoms as the initial symptoms.⁷ The oral lesions (enanthem) have detectable viral DNA particles in the oral and pharyngeal passages, even in the absence of skin lesions in the prodromal stage.^{27,28} Experiments in the infected animal model also found the highest concentration of virus in oral secretions,²⁹ irrespective of the route of infection (intradermally or intranasally).

Patients with nausea and/or vomiting and mouth sores may have a longer duration of hospitalization.⁸ The oral lesions on the oral epithelium, tongue, and

labial mucosa have shown epithelial hyperplasia, intracellular edema (ballooning degeneration), necrosis, ulceration, and scattered and poorly defined eosinophilic intracytoplasmic inclusion bodies.²⁹ The stratified squamous epithelium of the tongue also showed multinucleated syncytial cells.³⁰ Orthopoxvirus antigens were found only in the skin and oral cavity during the immunohistochemistry evaluation.²⁹ Although oral lesions are present in these studies, it can be a manifestation of comorbidities such as HIV infection.³¹

Mode of transmission

The exact mode of MPXV transmission to humans has not yet been confirmed. It can either be transmitted from animals to humans through direct or indirect contact with MPX-infected animals or their body fluids^{8,12} or from human-to-human transmission.^{32,33} The virus enters the body via damaged skin, the respiratory tract,

Table I. Oral lesions in human monkeypox disease and their management

<i>Author, Country</i>	<i>Age/Age range</i>	<i>Sample size; Study design</i>	<i>Oral lesions</i>	<i>Prevalence of oral lesions</i>	<i>Management of oral lesions</i>	<i>Comments</i>
Huhn et al., ⁸ USA	Age 6-47 y Median age: 26 y	34 patients; Retrospective observational study	Mouth sores and dysphagia (6/34)	17.6%	Not mentioned	Patients with nausea and/or vomiting and mouth sores had a longer hospitalization duration and pronounced lymphadenopathy.
Yinka-Ogunleye et al., ¹⁴ Nigeria	11 y	1 patient Case report	Oral mucosal lesions and ulcers	Case report	Not mentioned	Generalized lymphadenopathy.
Vaughan et al., ¹³ UK	Middle-aged men	2 patients Case reports	Progressive crops of vesicles and lesions on the mucosal surfaces of the mouth (1/2).	50%	Not mentioned	Not initially suspected of MPX infection because the first lesions appeared in the groin. Lymphadenopathy present.
Yinka-Ogunleye et al., ¹⁵ Nigeria	Age 2 d-50 y. Median age: 29 y	122 patients Clinical and epidemiologic report	58% of cases had a sore throat.	58%	Not mentioned	84/122 cases were male. Face was most commonly involved. All 122 cases had vesiculopustular rash.
Thornhill et al. ⁷ 16 countries, 943 sites	Mean age: 38 y	528 patients Observational study	Lesions with prodrome occurred in 17/30 cases. Isolated oral lesions in 13/30 cases. Within 7 d, ulcers on the tongue, corner of the mouth, and perioral umbilicated and vesicular lesions appeared. Pharyngitis, oropharyngitis, epiglottitis, and tonsillar lesions.	43.33%	Not mentioned specifically. Antiviral treatment, hospitalization for management of severe anorectal pain, and tissue superinfection.	Oropharyngeal symptoms were reported as the initial symptoms in 26/528 cases. Transmission is suspected through sexual activity in 95% of the infected persons. Generalized lymphadenopathy.
Patel et al., ¹⁶ UK	Age 12-67 y Median age: 38 y	197 patients Descriptive Case-series	27/197 patients had oral lesions	13.70%	No specific management for oral lesions.	All 197 participants were men. 196 were gay or bisexual. Tonsillar signs were seen in 9/197 cases, and sore throat in 33/197 cases. Lymphadenopathy in most cases.
Girometti et al., ¹⁷ UK	Median age: 41 y (IQR 34-45).	54 patients Observational study	4/54 had an oropharyngeal lesion	7.40%	No specific management for oral lesions. Admission to hospital, mainly due to pain or localized bacterial cellulitis requiring antibiotic intervention or analgesia.	Most cases were in MSM. High proportion of concomitant STIs. Local inoculation occurs during close skin-to-skin or mucosal contact.
Matias et al., ¹⁸ USA	Two men in their 20s, A third man in his 40s.	3 patients Case reports	Painful, pruritic vesiculo-pustular oropharyngeal lesions. Pustular lesions on his gingiva. Left tonsillar pain with associated oropharyngitis (2/3)	66.60%	Tecovirimat administered.	No prominent side effects of Tecovirimat 600 mg twice daily orally for 14 wk for systemic lesions.
Tarin-Vincente et al., ¹⁹ Spain	Median age: 37 y (IQR 31-42)	181 patients. Prospective cohort study	78/181 cases had lesions in the oral and perioral region	43.09%	Not mentioned	166/181 cases were MSM. 32/181 had smallpox vaccination. 73/181 cases had HIV.

(continued on next page)

Table I. Continued

Author, Country	Age/Age range	Sample size; Study design	Oral lesions	Prevalence of oral lesions	Management of oral lesions	Comments
Jang et al., ²⁰ Korea	34 y	1 patient Case report	Perioral erosive lesions covered with black crusts were found on his face	Case report	Not mentioned	Swabs and crusts were obtained from the perioral erosion after crust removal. Lymphadenopathy present.
Ajmera et al., ²¹ USA	26 y	1 patient Case report	Oral lesions, tongue swelling, burning sensation, multiple umbilicated pox-like perioral and oral lesions and oral candidiasis.	Case report	Magic mouth wash, IV fluconazole for oral thrush, and an IM dose of penicillin.	Past medical history of syphilis. Tenofovir/emtricitabine for HIV PrEP. Rashes on his tongue and perioral region.
Peiro-Mestres et al., ²² Spain	Age: 32-52 y Median age: 38.5 y	12 patients Case series	Oral and pharyngeal lesions (2/12)	16.60%	Not mentioned	Young adult MSM with a previous history of STIs. MPX DNA was detected in saliva samples collected between 4 and 16 d after the onset of symptoms.

MPX, monkeypox; MSM, men who have sex with men; STI, sexually transmitted infection; IM, intramuscular; IV, intravenous; PrEP, pre-exposure prophylaxis.

Table II. Oral manifestations in human monkeypox disease

Oral manifestations in patients with monkeypox disease	References
Oral ulcers	Huhn et al., ⁸ Girometti et al., ¹⁷ Peiro-Mestres et al. ²²
Oral mucosal lesions	Thornhill et al., ⁷ Huhn et al., ⁸ Yinka-Ogunleye et al. ¹⁴ Patel et al., ¹⁶ Ajmera et al., ²¹ Tarin Vincente et al. ¹⁹
Progressive crops of vesicles intraorally	Vaughan et al. ¹³
Ulcers on the tongue	Thornhill et al. ⁷ and Ajmera et al. ²¹
Epiglottitis and tonsillar lesions	Thornhill et al. ⁷ and Matias et al. ¹⁸
Pustular lesions on gingiva	Matias et al. ¹⁸
Oral thrush	Ajmera et al. ²¹
Perioral lesions	Tarin Vincente et al. ¹⁹ and Thornhill et al. ⁷
Perioral erosive lesions	Ajmera et al. ²¹ and Jang et al. ²⁰
Pharyngeal lesions	Thornhill et al., ⁷ Huhn et al., ⁸ Girometti et al., ¹⁷ Peiro-Mestres et al., ²² Matias et al. ¹⁸

or the mucous membranes of the eyes, nose, or oral cavity; large respiratory droplets; or direct or indirect contact with body fluids, lesion material, and contaminated surfaces, clothing, or linens. Local inoculation occurs during close skin-to-skin or mucosal contact.¹⁷ Disease progression in a prairie dog MPXV model suggests that virus shedding from the oral cavity begins before the onset of lesions.³⁴

Dentists should be vigilant when examining a suspected case of MPX because the primary lesions often originate in the oropharynx before manifesting on the skin.³ In some cases, oral samples,²⁶ including saliva,²² have been found to have the highest load of viral particles, and viral shedding could be detected in oropharyngeal secretions²⁶ before the development of generalized skin lesions. Viable MPX virus is seen in oral samples, including saliva,²² from days 9 to 18.²⁶ This is similar to the oral lesions seen in human orthopoxvirus disease²⁶ and increases the risk of MPX infection in dentists. Similarly, in some cases, perioral lesions extending to the face can also^{5,15} increase the risk of transmission. Severe pharyngitis in these patients might hinder the oral intake of food,⁷ which could be of particular significance in children and patients with comorbidities such as diabetes mellitus.

A possible sex predilection may be suggested based on the findings of the marmoset model of MPX. This experiment found more lesions and a lower viral burden (viremia and oral shedding) in women than in men.³⁵ However, in humans, oral lesions are mostly in

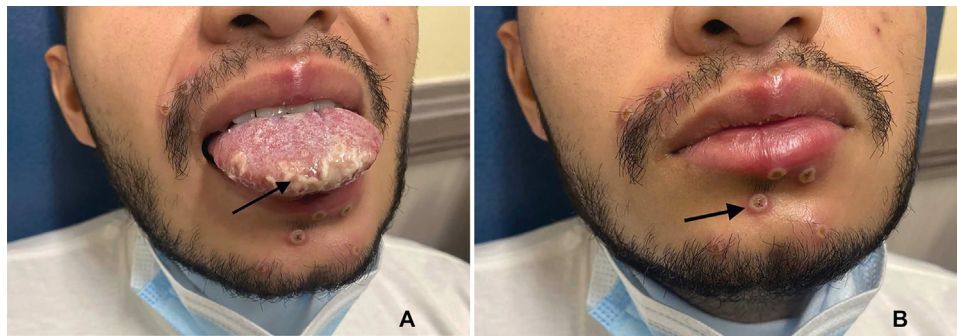

Fig. 2. (A) Perioral lesions in a 26-year-old male who tested positive for monkeypox polymerase chain reaction test. Arrow depicts umbilicated pox-like lesions of monkeypox disease. (B) Oral candidiasis and umbilicated lesions on the tongue in the same 26-year-old male patient. PCR, polymerase chain reaction. Photo credit: Ajmera KM, Goyal L, Pandit T, Pandit R. Monkeypox - an emerging pandemic. *IDCases*. 2022;29:e01587.

men^{15–17,19} in non-endemic regions such as the UK and Spain. A noteworthy finding was that most infected persons were gay or bisexual men; hence, transmission was suspected to occur through sexual activity.^{7,15,17,22} Many had a history of sexually transmitted infections (STIs).²² A report from 16 countries found that many MPX-infected men had human immunodeficiency virus infection.^{7,17,19,22} However, these well-controlled patients with HIV were on antiretroviral therapy (ART), and a very low HIV viral load (<50 copies per mL) was seen in most patients.⁷ There is also a change in the pattern of presentation of the clinical features of MPX infection.¹⁶ Travel history,¹³ history of contact with an individual with an MPX-like rash at a gathering,¹³ and consumption of bush meat¹³ have also been reported in patients with MPX disease.

Management of oral lesions of MPX disease

Most reports included in this review did not mention the specific management of oral lesions. Although it is self-limiting, prompt management is essential. Symptomatic treatment is the mainstay of therapy, especially during the prodromal phase.^{27,36,37} The interim rapid response guidance released on June 10, 2022 by the WHO recommends rinsing the mouth with saltwater at least 4 times a day in case of oral lesions. Oral lesions can cause secondary infections and facilitate person-to-person viral transmissions. A clean, moist microenvironment can mitigate transmission potential by covering infectious sores and promoting re-epithelialization of damaged exanthem. Using an oral antiseptic solution, such as chlorhexidine mouthwash, can keep the lesions clean. Alternatively, cleansing the ulcers with a dilute povidone-iodine solution will help maintain a hygienic microenvironment.²⁷ Application of local anesthetics such as viscous lidocaine will provide symptomatic relief.³⁸

Oral and topical analgesics or acetaminophen can be administered to control the pain in oral mucosal

lesions. Patients with secondary bacterial infections should be treated with appropriate antibiotics.²⁷ The use of non-steroidal anti-inflammatory drugs for pain relief should be limited owing to the concern of developing hemorrhagic lesions. Mucosal lesions of the mouth can be painful and warrant the use of appropriate analgesics.²⁷ “Magic mouthwash” along with intravenous fluconazole for oral candidiasis and an intramuscular dose of penicillin demonstrated symptomatic relief in a patient.²¹

Oral acyclovir may be prescribed at a prophylactic dose of 50 mg/kg given twice daily.³⁹ Many oropharyngeal lesions, such as tonsillar edema and odynophagia, can be relieved within 5 days when tecovirimat is administered for skin lesions.¹⁸ Based on the evidence from the previous epidemics, antivirals, smallpox vaccine, and vaccinia immune globulin can be effective⁴⁰ in controlling the outbreak since the MPX and smallpox viruses are related. Cidofovir, brincidofovir, and tecovirimat are antivirals suggested to defend against MPX⁴¹ infection and as a post-exposure prophylactic agent in exposed immunocompromised individuals who are contraindicated to receive the smallpox vaccine as a post-exposure prophylactic measure.^{42,43} Patients with oral lesions should be monitored for dehydration and malnutrition and should maintain good nutrition and hydration. Complications of illness include low mood and emotional lability, which may expose patients to poor oral health practices.⁵ Elective surgery should be deferred as long as the patient is infectious. Linens, hospital gowns, towels, and other fabrics should be carefully handled.

Precautions in dental clinics

Transmission can be prevented in dental care settings by taking standard, contact, and droplet infection control precautions when treating patients with MPX symptoms.^{3,44–46} The patient should be managed in isolation, and precautions should be taken to minimize

the exposure to surrounding individuals, such as covering any exposed skin lesions and placing a surgical mask over the patient's nose and mouth. In patients with probable or confirmed MPX infection, elective dental treatment should be deferred until the patient is no longer infectious.⁴⁷

CONCLUSIONS

Ulcers in the oral cavity or oropharynx can be the primary lesions compared with skin lesions in MPX cases. Oral ulcers have been recorded in almost one-quarter of patients with MPX infection. The lesions initially appear as pink macules or papules. Oral ulcers make it difficult for patients to consume food. Perioral blistered and ulcerated lesions have also been reported in several recent cases. The management of oral ulcerations includes symptomatic and supportive care, including the use of mouthwashes. Antiviral treatment and the use of antibiotics are recommended in severe cases and in cases with multiple lesions elsewhere in the body. Dental practitioners may be the first to detect the initial symptoms of MPX infection. Therefore, caution should be exercised, particularly when examining patients with fever and lymphadenopathy.

FUNDING

Funding for open access publishing has been received from Qatar national library.

DECLARATION OF INTEREST

none.

REFERENCES

- Phoolcharoen W, Shanmugaraj B, Khorattanakulchai N. Emergence of monkeypox: another concern amidst COVID-19 crisis. *Asian Pac J Trop Med.* 2022;15:193.
- Vivancos R, Anderson C, Blomquist P, et al. Community transmission of monkeypox in the United Kingdom, April to May 2022. *Euro Surveill.* 2022;27:2200422.
- Samaranayake L, Anil S. The monkeypox outbreak and implications for dental practice. *Int Dent J.* 2022;72:589-596.
- Perez Duque M, Ribeiro S, Martins JV, et al. Ongoing monkeypox virus outbreak, Portugal, 29 April to 23 May 2022. *Euro Surveill.* 2022;27:2200424.
- Adler H, Gould S, Hine P, et al. Clinical features and management of human monkeypox: a retrospective observational study in the UK. *Lancet Infect Dis.* 2022;22:1153-1162.
- Anderson MG, Frenkel LD, Homann S, Guffey J. A case of severe monkeypox virus disease in an American child: emerging infections and changing professional values. *Pediatr Infect Dis J.* 2003;22:1093-1096. discussion 1096-1098.
- Thornhill JP, Barkati S, Walmsley S, et al. Monkeypox virus infection in humans across 16 Countries - April-June 2022. *N Engl J Med.* 2022;387:679-691.
- Huhn GD, Bauer AM, Yorita K, et al. Clinical characteristics of human monkeypox, and risk factors for severe disease. *Clin Infect Dis.* 2005;41:1742-1751.
- Sookaromdee P, Wiwanitkit V. Mouth sores and monkeypox: a consideration. *J Stomatol Oral Maxillofac Surg.* 2022;123:593-594.
- Sukhdeo SS, Aldhaheeri K, Lam PW, Walmsley S. A case of human monkeypox in Canada. *CMAJ.* 2022;194:E1031-E1035.
- Ng OT, Lee V, Marimuthu K, et al. A case of imported monkeypox in Singapore. *Lancet Infect Dis.* 2019;19:1166.
- Petersen E, Abubakar I, Ihekweazu C, et al. Monkeypox - enhancing public health preparedness for an emerging lethal human zoonotic epidemic threat in the wake of the smallpox post-eradication era. *Int J Infect Dis.* 2019;78:78-84.
- Vaughan A, Aarons E, Astbury J, et al. Two cases of monkeypox imported to the United Kingdom, September 2018. *Euro Surveill.* 2018;23:1800509.
- Yinka-Ogunleye A, Aruna O, Ogoina D, et al. Reemergence of human monkeypox in Nigeria, 2017. *Emerg Infect Dis.* 2018;24:1149-1151.
- Yinka-Ogunleye A, Aruna O, Dalhat M, et al. Outbreak of human monkeypox in Nigeria in 2017-18: a clinical and epidemiological report. *Lancet Infect Dis.* 2019;19:872-879.
- Patel A, Bilinska J, Tam JCH, et al. Clinical features and novel presentations of human monkeypox in a central London centre during the 2022 outbreak: descriptive case series. *BMJ.* 2022;378:e072410.
- Girometti N, Byrne R, Bracchi M, et al. Demographic and clinical characteristics of confirmed human monkeypox virus cases in individuals attending a sexual health centre in London, UK: an observational analysis. *Lancet Infect Dis.* 2022;22:1321-1328.
- Matias WR, Koshy JM, Nagami EH, et al. Tecovirimat for the treatment of human monkeypox: an initial series from Massachusetts, United States. *Open Forum Infect Dis.* 2022;9:ofac377.
- Tarin-Vicente EJ, Alemany A, Agud-Dios M, et al. Clinical presentation and virological assessment of confirmed human monkeypox virus cases in Spain: a prospective observational cohort study. *Lancet.* 2022;400:661-669.
- Jang YR, Lee M, Shin H, et al. The first case of monkeypox in the Republic of Korea. *J Korean Med Sci.* 2022;37:e224.
- Ajmera KM, Goyal L, Pandit T, Pandit R. Monkeypox - an emerging pandemic. *IDCases.* 2022;29:e01587.
- Peiro-Mestres A, Fuertes I, Camprubi-Ferrer D, et al. Frequent detection of monkeypox virus DNA in saliva, semen, and other clinical samples from 12 patients, Barcelona, Spain, May to June 2022. *Euro Surveill.* 2022;27:2200503.
- Drago F, Ciccarese G, Merlo G, et al. Oral and cutaneous manifestations of viral and bacterial infections: not only COVID-19 disease. *Clin Dermatol.* 2021;39:384-404.
- Mahmoud A, Nchasi G. Monkeypox virus: a zoonosis of concern [e-pub ahead of print]. *J Med Virol.* <https://doi.org/10.1002/jmv.27968>, accessed September 14, 2022.
- Thakur S, Kelkar D, Garg S, et al. Why should RNA viruses have all the fun - monkeypox, a close relative of smallpox and a DNA virus. *J Glob Infect Dis.* 2022;14:47-49.
- Hutson CL, Olson VA, Carroll DS, et al. A prairie dog animal model of systemic orthopoxvirus disease using West African and Congo Basin strains of monkeypox virus. *J Gen Virol.* 2009;90:323-333.
- Koenig KL, Bey CK, Marty AM. Monkeypox 2022 Identify-Isolate-Inform: a 3I tool for frontline clinicians for a zoonosis with escalating human community transmission. *One Health.* 2022;15:100410.
- Reynolds MG, Yorita KL, Kuehnert MJ, et al. Clinical manifestations of human monkeypox influenced by route of infection. *J Infect Dis.* 2006;194:773-780.

29. Falendysz EA, Lopera JG, Doty JB, et al. Characterization of monkeypox virus infection in African rope squirrels (*Funisciurus* sp. *PLoS Negl Trop Dis*. 2017;11:e0005809.
30. Zaucha GM, Jahrling PB, Geisbert TW, Swearingen JR, Hensley L. The pathology of experimental aerosolized monkeypox virus infection in cynomolgus monkeys (*Macaca fascicularis*). *Lab Invest*. 2001;81:1581-1600.
31. Betancort-Plata C, Lopez-Delgado L, Jaen-Sanchez N, et al. Monkeypox and HIV in the Canary islands: a different pattern in a mobile population. *Trop Med Infect Dis*. 2022;7:318.
32. Nolen LD, Osadebe L, Katomba J, et al. Introduction of monkeypox into a community and household: risk factors and zoonotic reservoirs in the Democratic Republic of the Congo. *Am J Trop Med Hyg*. 2015;93:410-415.
33. Kalthan E, Tenguere J, Ndjapou SG, et al. Investigation of an outbreak of monkeypox in an area occupied by armed groups, Central African Republic. *Med Mal Infect*. 2018;48:263-268.
34. Hutson CL, Kondas AV, Mauldin MR, et al. Pharmacokinetics and efficacy of a potential smallpox therapeutic, Brincidofovir, in a lethal monkeypox virus animal model. *mSphere*. 2021;6:e00927-20.
35. Mucker EM, Wollen-Roberts SE, Kimmel A, Shamblin J, Sampy D, Hooper JW. Intranasal monkeypox marmoset model: prophylactic antibody treatment provides benefit against severe monkeypox virus disease. *PLoS Negl Trop Dis*. 2018;12:e0006581.
36. Afshar ZM, Rostami HN, Hosseinzadeh R, et al. The reemergence of monkeypox as a new potential health challenge: a critical review [e-pub ahead of print]. *Authorea*. <https://doi.org/10.22541/au.165446104.43472483/v1>, accessed September 14, 2022.
37. Durski KN, McCollum AM, Nakazawa Y, et al. Emergence of monkeypox - West and Central Africa, 1970-2017. *MMWR Morb Mortal Wkly Rep*. 2018;67:306-310.
38. France K, Villa A. Acute oral lesions. *Dermatol Clin*. 2020;38:441-450.
39. Hukkanen RR, Gillen M, Grant R, Liggitt HD, Kiem HP, Kelley ST. Simian varicella virus in pigtailed macaques (*Macaca nemestrina*): clinical, pathologic, and virologic features. *Comp Med*. 2009;59:482-487.
40. Russo AT, Berhanu A, Bigger CB, et al. Co-administration of tecovirimat and ACAM2000 in non-human primates: effect of tecovirimat treatment on ACAM2000 immunogenicity and efficacy versus lethal monkeypox virus challenge. *Vaccine*. 2020;38:644-654.
41. Siegrist EA, Sassine J. Antivirals with activity against monkeypox: a clinically oriented review [e-pub ahead of print]. *Clin Infect Dis*. <https://doi.org/10.1093/cid/ciac622>, accessed September 14, 2022.
42. Baker RO, Bray M, Huggins JW. Potential antiviral therapeutics for smallpox, monkeypox and other orthopoxvirus infections. *Antiviral Res*. 2003;57:13-23.
43. Xiao Y, Isaacs SN. Therapeutic vaccines and antibodies for treatment of orthopoxvirus infections. *Viruses*. 2010;2:2381-2403.
44. Cunha BE. Monkeypox in the United States: an occupational health look at the first cases. *AAOHN J*. 2004;52:164-168.
45. Samaranayake L. *Essential Microbiology for Dentistry*. Maryland Heights, MO: Elsevier Health Sciences; 2018.
46. Tsagkaris C, Eleftheriades A, Laubscher L, Vladyckuk V, Papadakis M. Viruses monkeying around with surgical safety: monkeypox preparedness in surgical settings [e-pub ahead of print]. *J Med Virol*. <https://doi.org/10.1002/jmv.27915>, accessed September 14, 2022.
47. Samaranayake L, Anil S. *Monkeypox and the dental team*. *Dental Update*. 2022;49:683-687.